

Natural Coral-Based Bone Substitutes

Haim Tal

DMD, MDent, PhD

Professor of Periodontology, Department of Periodontology and Oral Implants Tel Aviv University School of Dental Medicine.

The author is a senior consultant for Core Bone Ltd., Israel

Highlights

- Coral granules are bone-like osteoconductive porous biomaterials.
- Coral granules are xenografts that can be used as scaffolds in bone growth sites and for augmentation procedures.
- Corals grow well under controlled conditions in aquarium-like pools.
- The final coral composition is affected by various environmental conditions, such as water salinity, temperature and nutrients.

Abstract

Bone grafts are an integral component of most oral rehabilitation treatment programs. The similarity between the characteristics of bones and natural coral in terms of composition, structure, strength and resorption qualities, has led to the widespread use of coral-derived materials in orthopedics and dentistry, particularly for bone augmentation. The use of coral-based xenografts allows circumventing some of the inherent

complications associated with the use of autogenous implants and allografts. This article describes the unique qualities of the natural coral skeleton that grows in an optimal artificial environment, making it an ideal biomaterial for bone substitutes.

Keywords:

Bone augmentation, oral rehabilitation, coral, xenograft, bone substitute

Introduction

Following tooth extraction, various intra-alveolar and extra-alveolar processes – mainly bone resorption - take place in the alveolar process and ridge (Figure 1) [1, 2]. This pathological bone loss may decrease significantly if graft material is placed in the fresh extraction socket (Figure 2). The introduction of immediate implant placement, especially at sites in which post-extraction bone resorption is prominent, has made bone augmentation procedures a frequent and integral part of most treatment plans and implant procedures [3, 4]. Therefore, the use of osseointegrated oral implants, has made improving bony contours of the jaws and increasing bone volume at implant sites an issue of utmost importance in oral rehabilitation.

Autogenous grafts are considered the “gold standard” in oral surgery. Such grafts are commonly harvested from the posterior mandible, iliac crest, ribs, femur or parietal bone of the patient, but the harvesting procedure increases operative time, donor-site morbidity and costs (Figure 3). Additional factors that may lead to complications include handling bone contour to achieve its appropriate size and individual variations in bone resorption [4]. Human-derived allografts (a graft from a human donor that is not genetically identical to the recipient), and bovine/porcine bone

grafts (xenografts) are more available than autogenous grafts and as such are more commonly used for bone augmentation. However, these grafts carry potential risks for immunogenicity and disease transmission [6, 7]. They pass through viral and prion elimination process that cause loss of essential bone-like and resorption qualities. Furthermore, in Europe, the use of allografts is limited due to legal issues [5, 6].

Use of coral-based bone substitutes

Natural coral skeleton is morphologically and

The structure and chemical composition of coral is similar to bone, making it a suitable biological material for bone grafting, and circumventing some of the inherent complications associated with the use of autografts and allografts.

chemically similar to native bone. Porous coralline granules derived from natural corals have several attributes that render them a suitable biomaterial for bone substitution in bone augmentation procedures, while bypassing some of the inherent complications associated with the use of autogenous grafts and allografts. These include osteoconduction (meaning that they can serve as a scaffold for bone growth) and resorption. In addition, the coral bone substitute (CBS) does not evoke inflammatory infiltrate or fibrous encapsulation^[8, 11].

Since they were first developed, in the 1980s, coral (coralline) grafts have been successfully used worldwide to treat a variety of orthopedic, craniofacial and oral bony defects, and to enable osseous augmentation procedures. Numerous pre-clinical and clinical studies, including ones with longitudinal follow-up, have demonstrated successful augmentation using natural coral skeleton, indicating that both natural coral and coralline hydroxyapatite are biocompatible, osteoconductive and resistant to infections^[8, 9]. Several studies have shown that calcium carbonate-rich grafts (BioCoral, France) induced new bone formation after maxillary sinus augmentation^[10-13]. A study that compared maxillary sinus augmentation responses to tissue-engineered bone graft obtained by a culture of autogenous osteoblasts seeded on polyglycolic-poly-lactic scaffolds (Oral Bone®, BioTissue, Germany) versus calcium carbonate (BioCoral, France), showed that the mean of new bone tissue in the grafted area was 37% and 55%, respectively^[12]. A clinical follow-up of socket

Figure 1: Dry mandible specimens showing:

(a) an occlusal view of an extraction socket of a first molar tooth. (b) A cross section of a similar socket. The red line represents the new contour expected to develop a few months after the extraction due to post-extraction bone resorption and bone remodeling. (c) a posterior mandible cross section showing the diminished contour of the newly remodeled bone ridge one year after the extraction.

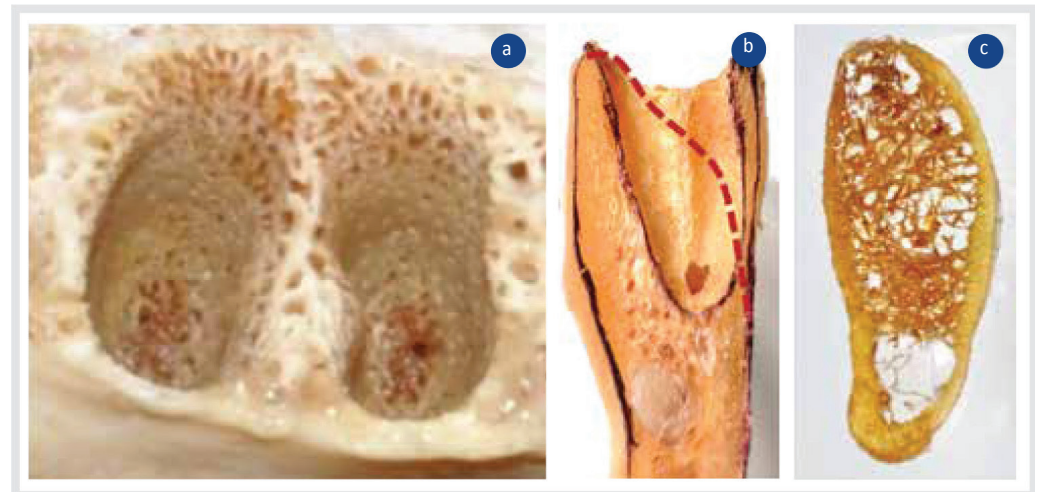


Figure 2: Immediate implant placement in a fresh mandibular molar extraction socket.

(a) A clinical view of a threaded implant placed in a fresh extraction socket. The implant shoulder is located 1-2 mm below the socket bone margins. (b) The space between the alveolar bone and implant's surface is filled with coral bone. This will be covered with a resorbable collagen membrane and gingival flaps. (c) Radiographic examination 6 months after the surgical procedure reveals a radiopaque zone peripheral to the implant, clearly lining the socket margins. (d) Final restoration with a zirconia crown that fulfills the functional and esthetic expectation.

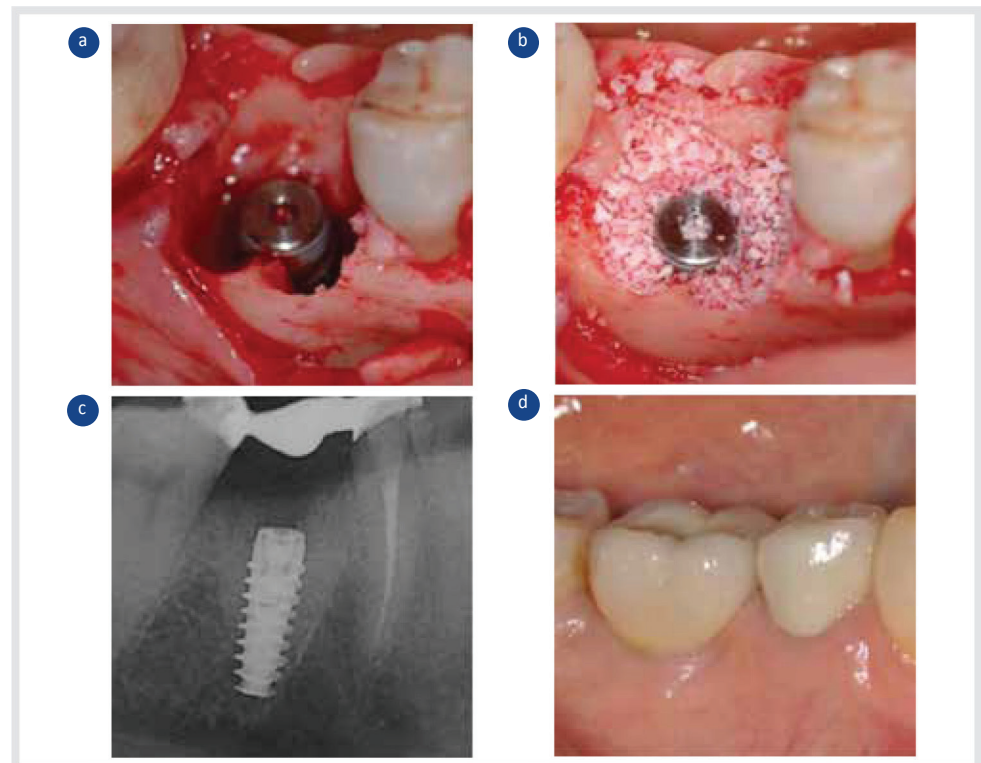
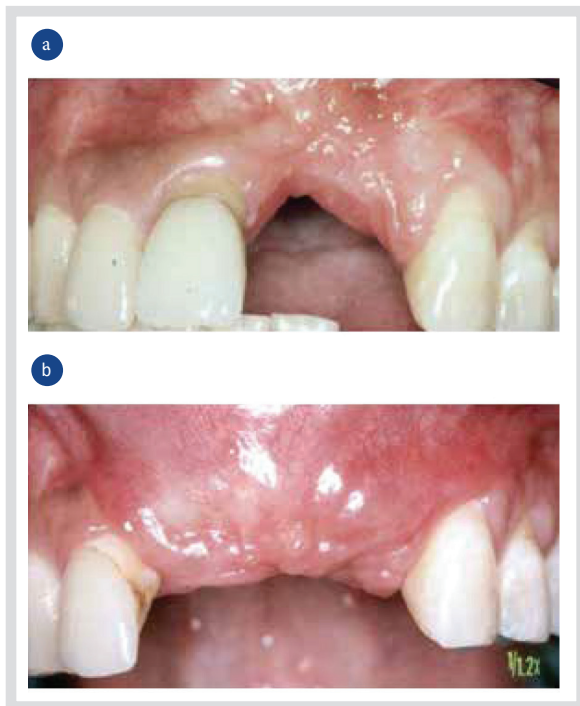

Fig. 3 Reconstruction of the premaxilla after traumatic injury involving the face

(a) Clinical view of upper front maxilla, six months after injury and loss of the upper left incisors (#21,#22), (b) Clinical view of same site, six months after grafting the maxillary defect with an autogenous parietal bone after removing the upper right central incisor (#12). Note that the alveolar ridge height is now ready for implant placement . fulfilling most requirements of the upper jaw esthetic demands



CoreBone corals grow in closed monitored environment within aquarium system, using laboratory sea-like water enriched with bioactive nutrients (patented)

preservation procedures using CBS in the posterior maxilla and mandible demonstrated that 93.5% of the augmentation sites were successful in supporting endosseous dental implant placement without requiring additional augmentation procedures. Hence, in successful sites, coral granules can spare residual ridge atrophy and resorption, obviating the need for additional augmentation aids

and reducing treatment and costs (Figure 4).

Histological analyses of core specimens harvested during implant placement in sites that were previously treated with coral grafts, revealed no foreign body reaction to coral grafted particles^[8]. Histochemical analysis showed no presence of osteoblasts positive for alkaline phosphatase, and mineralized tissue analysis (von Kossa stain) demonstrated a mature and highly mineralized bone around the grafted particles^[15]. Figure 5 shows a computerized histometric analysis of a typical non decalcified section harvested from a xenograft-augmented antral sinus floor. The fact that almost all grafted particles were in contact with mature bone supports the claim that this biomaterial is highly osteoconductive. Notably, no fibrous tissue encapsulation was observed^[14, 15].

Coral bone xenograft production and quality

As mentioned above, the bone-like properties of natural coral, in terms of qualities, composition, structure, strength and resorption, have led to their popular use in dental and orthopedic procedures. However, in the last decade, corals have been declared endangered species and their quality has deteriorated due to sea pollution. CoreBone has recently developed a biomimetic CBS composed of pure coral minerals. This product consists of >95% calcium carbonate crystals in the form of aragonite enriched with silicium, strontium, and other non-organic substances. The three main elements - calcium, silicium and strontium - play an important role in bone mineralization and activation of enzymatic reactions in osteogenic cells (Figure 6).

Silicium and strontium contribute to the strength of the CBS, which is up to 5 times higher than that of synthetic or cancellous bones (Table 1). The CBS comprises a combination of coral types which mimic cortical and cancellous bones and allow optimal bone growth and remodeling using osteoclasts. Its porous structure enables vascular ingrowth and the formation of new bone (Figure 7). Unlike previous products, CoreBone CBS is produced from corals that are grown in a closed, controlled aquatic system (aquarium) that is fed by proprietary technology-laboratory-made sea water enriched with bioactive nutrients. This coral growing technology allows utilizing the bone-like properties of corals while avoiding sea pollution-related risks (Figure 8). Because the structure of corals is affected by its environment (e.g., salinity, minerals, temperature), the controlled aquatic system enables growing various types of corals, with each type having specific porosity, strength and shape, and used for a different indication in dentistry and orthopedics. Below are three examples of cases in which CoreBone CBS were used for augmentation and oral defect rehabilitation.

Case 1

Socket preservation after extraction of the right mandibular first molar (#46). Granule size: 600-1000 µm. Figure 9 shows a large bony defect that left the bone contours and volume unsuitable for implant placement.

Case 2

Sinus floor elevation in an edentulous posterior ridge. An “open” lateral window approach procedure was performed in

the right maxilla using 1 gram of coral bone granules, sized 600-1000 μm . Eight months after the procedure 3 implants were placed. Figure 10 shows a 2-mm wide core of hard tissue harvested from the osteotomy and stained for histological examination.

Case 3

Augmentation of a large bony defect in the right posterior maxilla, following periapical cyst removal and a sinus lift procedure. CoreBone 1000 with granule size 600-1000 μm was used (Figure 11).

Conclusions

The similar characteristics of natural coral and bone, in terms of qualities, composition, structure, strength, and resorption, have led to the widespread use of coral-derived materials in dentistry and orthopedics. Coral granules are appropriate for use as bone substitutes in augmentation procedures because they are osteoconductive porous materials. Corals grow well under controlled conditions in aquarium-like pools, with different environmental conditions affecting the composition of the desired final product.

Coral-bone, like human bone allografts is resorbable. Osteoclastic resorption does not occur to bovine xenografts due to the structural changes as a result of prion (Mad Cow Disease) inactivation proces

Figure 4:

(a) Radiographic view of an extraction socket site of tooth #25, 4 months after being grafted with CoreBone 1000. The radio-opaque area shows new bone and graft particles. (b) Radiographic view 5 months after the extraction showing 2 implants that were placed at sites #25 and #26. (c) Histological view (trichrome stain, X100 magnification) of cores taken from the augmented site before implant insertion, reveals new woven (blue) and calcified (red) bone growth surrounding coral particles (empty), bone marrow connective tissue and (d) Histological view (trichrome stain, X100 magnification) shows new bone growth centers.

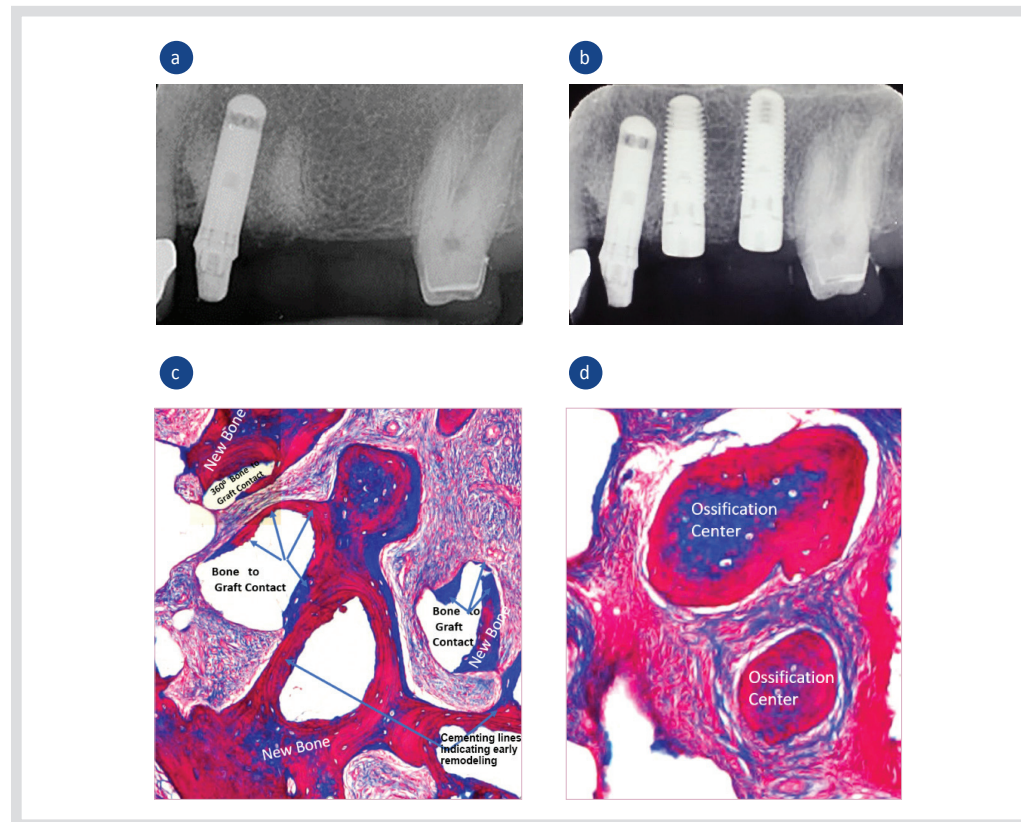


Figure 5: A histological section of a core harvested from an antral sinus floor augmented with bone graft particles. (a) Almost all grafted particles are in contact with new bone. (b) Computerized histometric analysis further supports the microscopic observation.

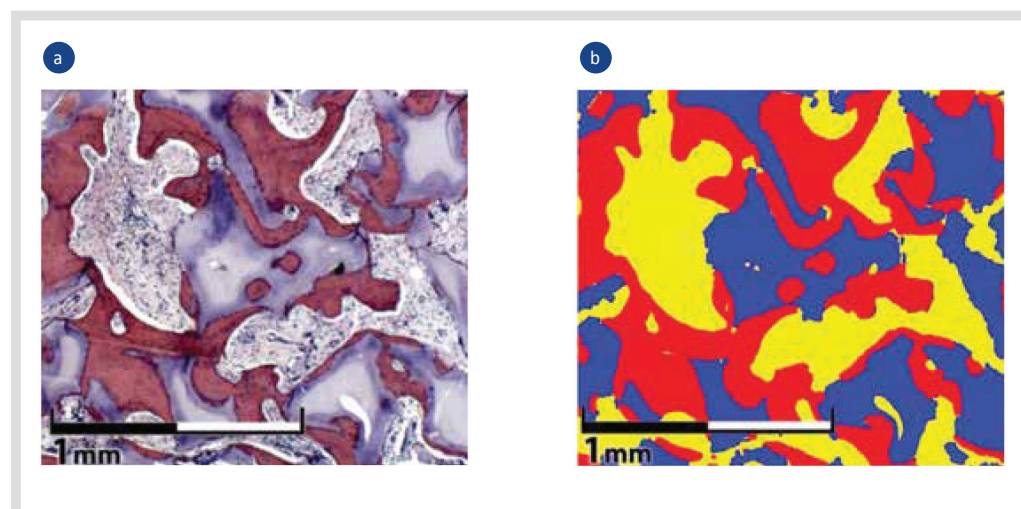


Figure 6:

(a) Core Bone coral porous structure. (b) Higher magnification shows the bioactive surface and interconnected pores in optimal dimensions for ingrowth of blood vessels and bone deposition. Scanning electron microscope images showing similarity between (c) CoreBone CBS and (d) human bone mineralized tissue scaffolds.


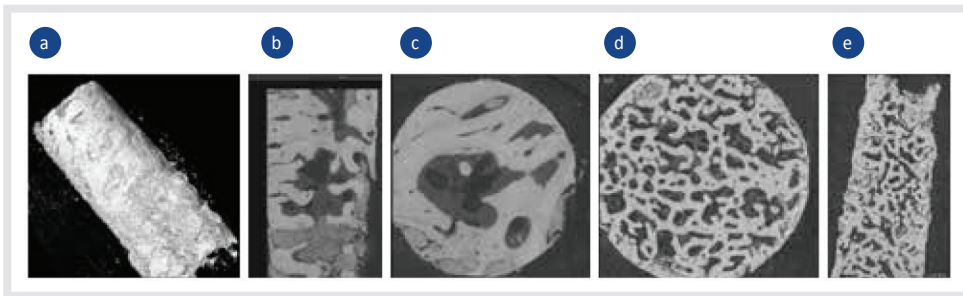


Figure 7:

(a) Micro computed tomography (CT) 3D view of a cylindrical core harvested from a canine extraction socket grafted with coral bone. (b) Longitudinal section and (c) Cross section of the middle of the core taken 4 weeks after the extraction and showing woven bone filling the socket. (d) Cross section and (e) longitudinal section of the middle of the core taken 8 weeks after the extraction and showing dense, well organized cancellous bone filling the socket



Tab 1. The physical characteristics of CoreBone and other bone substitutes

Bone/bone substitute	Ultimate tensile strength (MPa)
CoreBone	17-22
Sea coral (other brands)	3-8
Cancellous bone	3.5-7
Synthetic bone	2-5

Figure 8:

(a) The CoreBone aquarium provides sea-like water, enriched with bioactive nutrients. (b) Natural coral growth in CoreBone artificial environment. (c) Final sterilized CorerBone graft.




Figure 9: A large bony defect with bone contours and volume that are unsuitable for implant placement. (a) Cross section and (b) longitudinal section of a large bony defect with bone contours and volume unsuitable for implant placement. (c) Cross section and (d) longitudinal section of the same site 6 months after augmentation (before implant placement), showing that the graft material was integrated with the host bone, eliminating the defect and providing a suitable site for implantation.

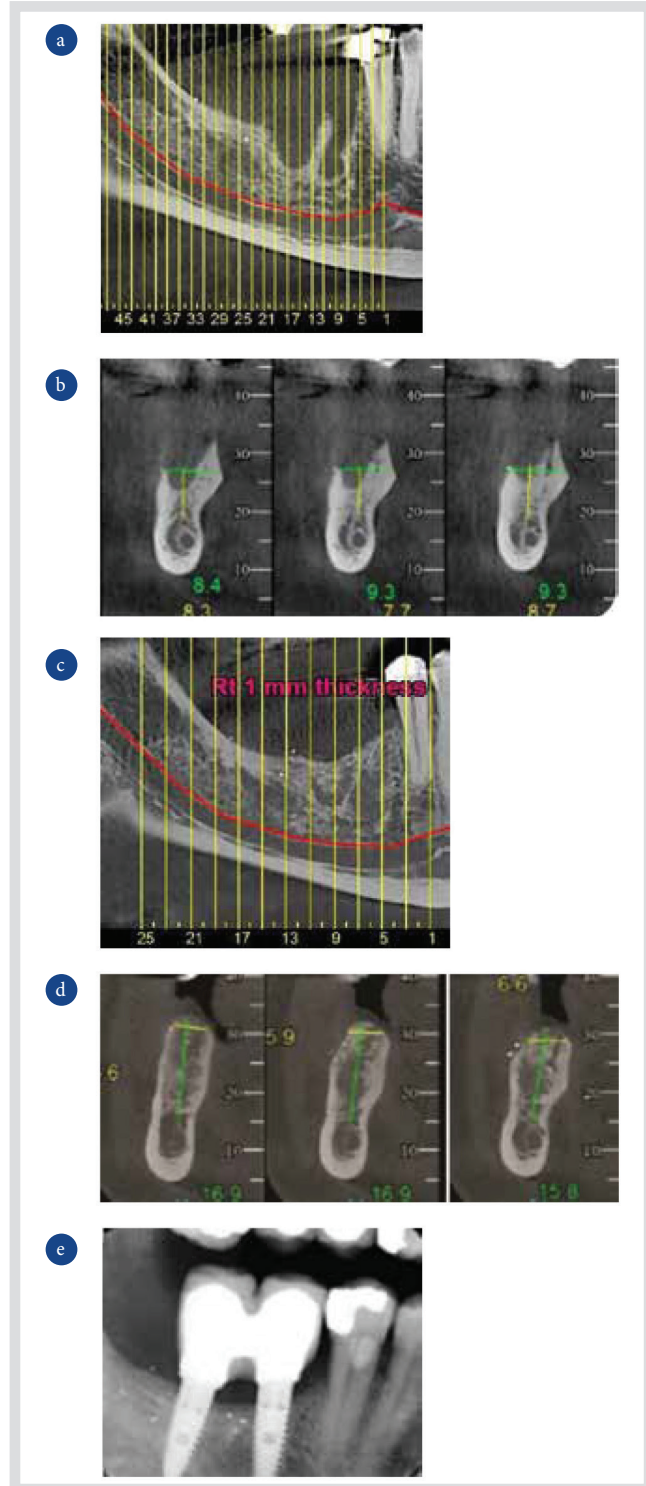


Figure 10: A histologic section (haematoxylin and eosin stain, original magnification X100) of a core trephined from an edentulous upper posterior ridge, 8 months after a sinus lift procedure. The sinus was augmented with CoreBone particles 600-1000 µm. The ridge zone (bottom) presents mainly pristine cancellous bone (PB) and Bone Marrow (BM). The upper zone reveals few graft particles (CB) partly surrounded by New Bone (NB) indicating high graft conductivity.

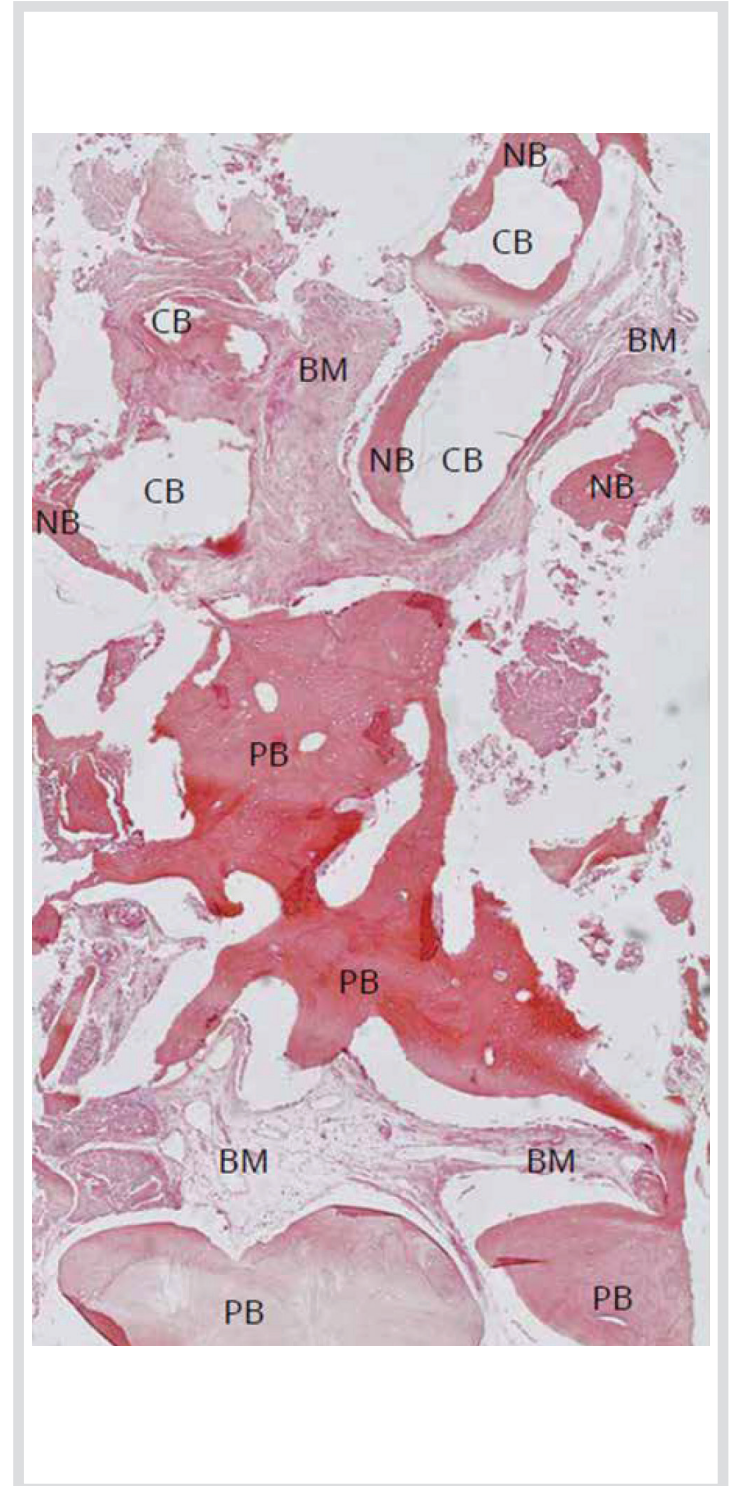
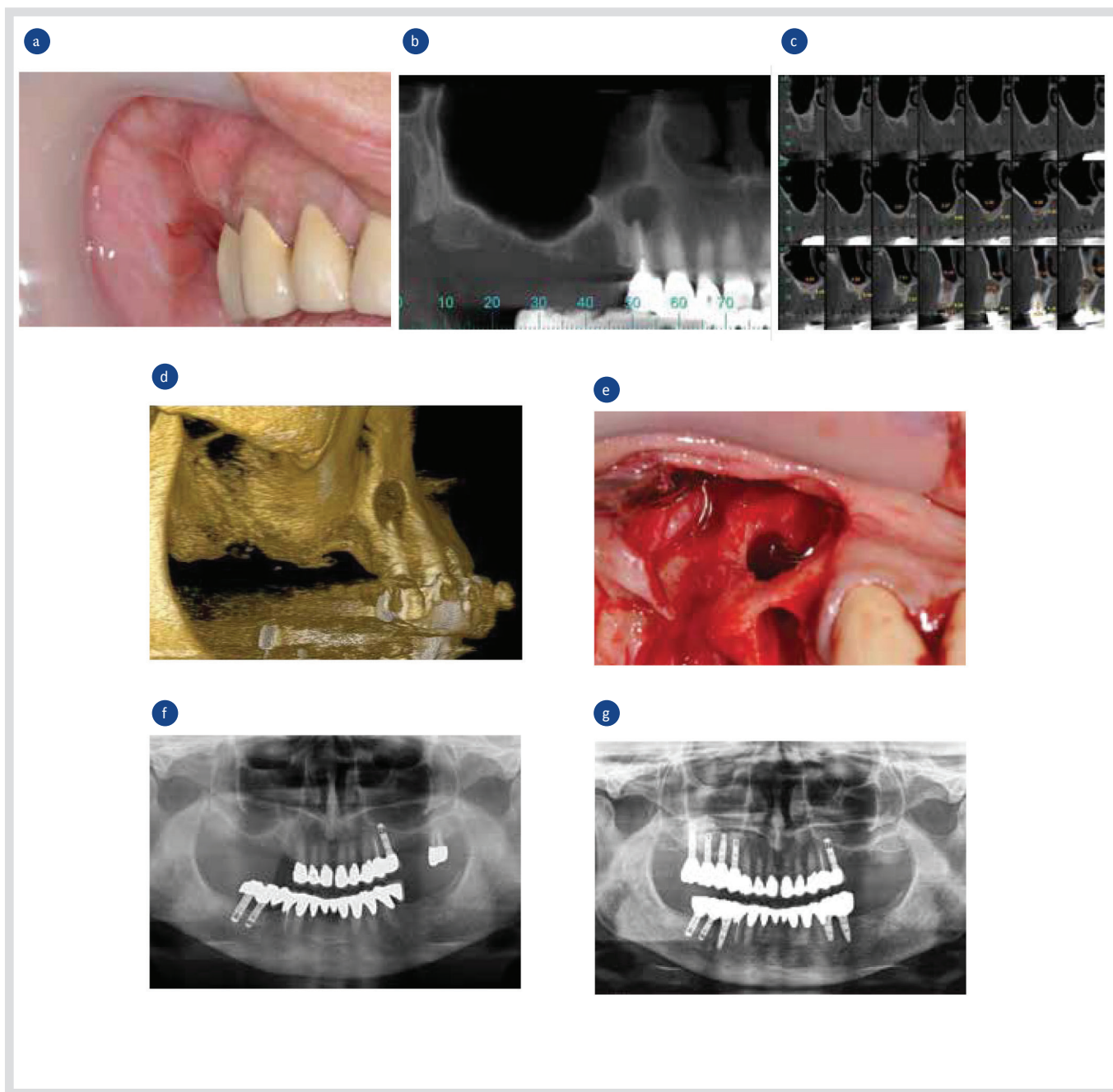


Figure 11:

(a) An initial site showing buccal swelling at the buccal aspect of the upper first right premolar tooth (#14). (b) A longitudinal section taken by CT of the bony defects at the first and second premolar teeth (#14, #15). (c) A cross section taken by CT of the upper right posterior maxilla showing bone loss in the molar region, resulting in a thin (1-2 mm) sinus floor and periapical defect associated with the first premolar. (d) A 3D image of the upper right posterior maxilla showing severe bone loss in the molar region and a periapical defect associated with the first premolar. (e) A surgical view of the upper right posterior maxilla showing severe bone loss in the posterior maxillary ridge (molars and second premolar tooth) and an extraction socket and periapical defect associated with the first premolar. (f) Five months after surgery: a panoramic view of the defects augmented using CoreBone 1000. (g) Eight months after surgery: a panoramic view of the augmented defects that was followed by placement of 4 implants and construction of an implant-supported fixed prosthesis.



References

1. Amler MH, The time sequence of tissue regeneration in human extraction wounds. *Oral Surg Oral Med Oral Pathol*, 1969;27:309-318.
2. Auraújo MG, Lindhe J, Dimensional ridge alterations following tooth extraction: An experimental study in the dog. *J Clin Periodontol*, 2005;32:212-218.
3. Souyris F, Pellequer C, Payrot C, Servera C, Coral, a new biomedical material. Experimental and first clinical investigations on Madreporaria. *J Maxillofac Surg*, 1985;13:64-69.
4. Molly L, Vandromme H, Quirynen M & al, Bone Formation Following Implantation of Bone Biomaterials Into Extraction Sites; *J Periodontol* 2008;79:1108-1115
5. Boyce T, Edwards J, Scarborough N, Allograft bone. The influence of processing on safety and performance. *Orthop Clin North Am*, 1999;30:571-581.
6. Sheikh Z, Sima C, Glogauer M, Bone replacement materials and techniques used for achieving vertical alveolar bone augmentation. *Materials (Basel)*, 2015;8:2953-2993.
7. Kenley RA, Yim K, Abrams J & al, Biotechnology and bone graft substitutes. *Pharm Res*, 1993;10:1393-1401.
8. Piattelli A, Podda G, Scarano A, Clinical and histological results in alveolar ridge enlargement using coralline calcium carbonate. *Biomaterials*, 1997;18:623-627.
9. Begley CT, Doherty MJ, Mollan RA & al, Comparative study of the osteoinductive properties of bioceramic, coral and processed bone graft substitutes. *Biomaterials*, 1995;16:1181-1185.
10. Figueiredo M, Henriques J, Martins G & al, Physicochemical characterization of biomaterials commonly used in dentistry as bone substitutes - comparison with human bone. *J Biomed Mater Res B Appl Biomater*, 2010;92:409-419.
11. Demers C, Hamdy CR, Corsi K & al, Natural coral exoskeleton as a bone graft substitute: a review. *Biomed Mater Eng*, 2002;12:15-35.
12. Mangano C, Piattelli A, Mangano A & al, Combining scaffolds and osteogenic cells in regenerative bone surgery: a preliminary histological report in human maxillary sinus augmentation. *Clin Implant Dent Relat Res*, 2009;11: e92-e102.
13. Sândor GK, Kainulainen VT, Queiroz JO & al, Preservation of ridge dimensions following grafting with coral granules of 48 post-traumatic and post-extraction dento-alveolar defects. *Dent Traumatol*, 2003;19:221-227.
14. Magan A, Ripamonti U, Geometry of porous hydroxyapatite implants influences osteogenesis in baboons (*Papio ursinus*). *J Craniofac Surg*, 1996;7:71-78.
15. Walsh WR, Chapman-Sheath PJ, Cain S & al, A resorbable porous ceramic composite bone graft substitute in a rabbit metaphyseal defect model. *J Orthop Res*, 2003;21:655-661.

* Dr. Yaakov Levi DMD. Case: Figure 9

** Dr. Jaroslaw Pospiszech DMD. PhD. Case: Figure 10

*** Prof. José Luis Calvo Guirado D.D.S, PhD. Case: Figure 7